

Complete Resorption of Large Cervical Disc Protrusion Compressing Spinal Cord

Jae Hyun Park*, Hojoon Ki, Juhyun Yoon, Ho Tae Ji, Sung Jun Hong

Department of Anesthesiology and Pain Medicine, Kangdong Sacred Heart Hospital, Hallym University Medical Center, Seoul, 445 Gil-dong, Gangdongu Seoul, Republic of Korea 134-701

DOI: [10.36347/sjmcr.2021.v09i09.015](https://doi.org/10.36347/sjmcr.2021.v09i09.015)

| Received: 09.06.2021 | Accepted: 06.07.2021 | Published: 18.09.2021

*Corresponding author: Jae Hyun Park

Abstract

Case Report

In this report, we describe a case of 32-year-old woman who experienced spontaneous resolution of a large herniated disc with cord compression at C5-6. While the need for a surgical procedure is commonly accepted in case of symptomatic myelopathy, the medical management of cases with no or mild symptomatic lesion may be debated [1]. The following manuscript describes a case of spontaneous regression of herniated cervical disc and suggests that, even in patient with acute cervical disc herniation accompanied with cervical myelopathy, non-surgical, conservative treatment could be an option.

Keywords: Resorption of Large Cervical Disc Protrusion Spinal Cord.

Copyright © 2021 The Author(s): This is an open-access article distributed under the terms of the Creative Commons Attribution 4.0 International License (CC BY-NC 4.0) which permits unrestricted use, distribution, and reproduction in any medium for non-commercial use provided the original author and source are credited.

INTRODUCTION

Cervical herniated intervertebral disc (HIVD) is a condition which arises from compression of cervical spinal nerve root by the degenerated disc. The majority show clinical improvement with conservative treatment or surgical treatment, but there is no consensus regarding the indication and timing for surgical treatment of cervical myelopathy with no or mild neurologic deficits [1]. The concept of resorption of herniated nucleus pulposus (HNP) was first described in the 1980s and spontaneous regression of cervical disc herniation was first described by Krieger and Maniker in 1992 [2, 3]. Limited data are available in the literature about spontaneous regression of cervical disc herniation compared to lumbar disc herniation. We report the spontaneous disappearance of acute cervical disc herniation in patient with cervical cord compression.

CASE REPORT

A 32-year-old woman developed acute onset neck pain radiating to the right upper extremity, with a C5-6 dermatome distribution. The patient reported mild numbness and tingling sensation. Her motor examination revealed 4/5 strength on right elbow flexion, extension and grasping. She had no other motor weakness, bowel or bladder dysfunction or difficulty with gait. All reflexes were normal. An initial MRI scan demonstrated a large central to right subarticular disc

protrusion at C5-6, which compress spinal cord. C6-7 central disc protrusion and loss of cervical lordosis was also demonstrated (Figure 1).

A soft cervical collar and medical treatment including gabapentin, non-steroidal anti-inflammatory drugs (NSAIDs) and muscle relaxant have been applied to the patient since the first diagnosis. C5-6 epidural block with steroid, dexamethasone 5mg, was done and pain was relieved. After three times of epidural block for two weeks, she was hospitalized for rehabilitation therapy and consulting the need for surgery with neurosurgeon. The neurosurgeon recommended surgical intervention since there was definite cord compression and possibility of neurological deterioration, but the patient rejected for the fear of surgery. After warning of red flag sign including myelopathy symptoms, she was discharged with frequent follow-up schedule.

The medical treatment have been applied for 6 month after her initial presentation, and her symptoms were improved to the point of no longer requiring medical therapy or a cervical collar. Her neck pain and radicular symptoms resolved, and her upper extremity motor, sensory, and reflex examination was normal without evidence of myelopathy. Repeated MRI was done after 11 months from her initial MRI. In this MRI, resorption of right central to subarticular extruded disc and decompression of spinal cord was observed (Figure 2). The patient returned to the status before her

symptoms occurred, and has experienced no recurrence of symptoms at least 7 months after resolution of her symptoms.

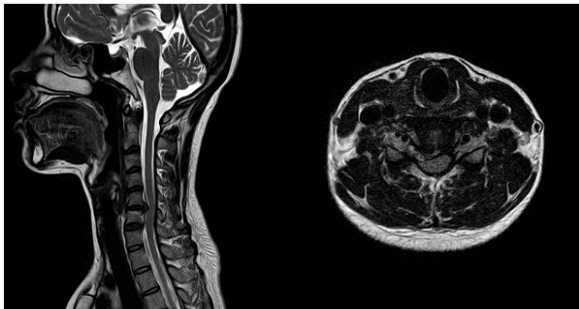


Fig-1: T2-weighted sagittal and T2 weighted axial magnetic resonance images from initial presentation

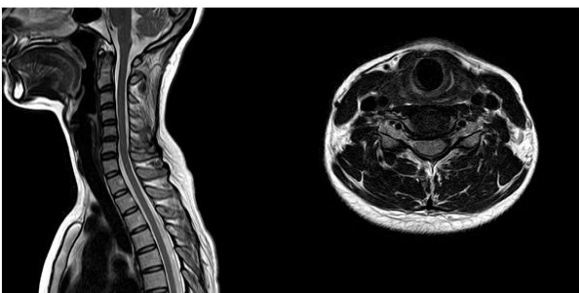


Fig-2: T2-weighted sagittal and T2 weighted axial magnetic resonance images at 11 month follow up

DISCUSSION

Cervical disc herniation is an increasing health problem by decreasing quality of life and limiting the function of musculoskeletal system. Surgical or medical treatment can be applied according to the symptom and clinical sign of the patient. For the patients with severe myelopathy sign, surgical approaching is widely accepted. For the patients with no or mild symptoms, even in case of cord compression, the non-surgical treatment including non-steroidal anti-inflammatory drugs, analgesics, muscle relaxant and neck collar may be debated.

The resorption of herniated discs with non-surgical treatment has been reported and widely recognized since its first report in the 1980s [3]. Spontaneous regression of cervical disc was first described by Krieger and Maniker in 1992 [5]. Rahimizadeh et al. have reported 26 cases and Okan Turk et al. reviewed 14 cases retrospectively which showed resorption of cervical disc herniation [7, 8].

Three possible hypotheses exist, each of which explain the process of disc regression. First hypothesis states the retraction of herniated disc back into the intervertebral space. According to the second hypotheses, gradual dehydration and shrinking makes the herniated fragment disappears. Third are inflammatory reaction, neovascularization and

phagocytosis caused by herniated disc in the epidural space, which means the extruded disc is suggested to be perceived as a foreign body [6].

We present a case of cervical disc herniation compressing spinal cord. Based on her symptom including mild motor weakness, tingling sensation and numbness, and MR imaging, surgical treatment was recommended but not applied. After about 6 months of non-surgical treatment her symptoms were improved and the repeated MR imaging showed definite resorption of disc herniation. According to the results of this case and the previous study of above, non-surgical treatment seems to be a good option in patient who have radiculopathy or even myelopathy, who do not have severe neurologic deficit and who do not require urgent surgery. And also, physicians caring patient on medical therapy, not surgery, need to consider the potential for regression in the evaluation and management of patients. Cervical epidural interlaminar block can provide effective pain relief in the interval for this patient [9].

REFERENCES

1. Brauge, D., Madkouri, R., Clément, R., Reina, V., Brauge, T., & Gaillard, S. (2017). What are the possibilities of spontaneous resorption of a thoracic disc herniation occupying more than 20% of the spinal canal in the asymptomatic subject? Comparative study. *Journal of Clinical Neuroscience*, 44, 269-273.
2. Krieger, A. J., & Maniker, A. H. (1992). MRI-documented regression of a herniated cervical nucleus pulposus: a case report. *Surgical neurology*, 37(6), 457-459.
3. Teplick, J. G., & Haskin, M. E. (1985). Spontaneous regression of herniated nucleus pulposus. *American journal of roentgenology*, 145(2), 371-375.
4. Mochida, K., Komori, H., Okawa, A., Muneta, T., Haro, H., & Shinomiya, K. (1998). Regression of cervical disc herniation observed on magnetic resonance images. *Spine*, 23(9), 990-995.
5. Krieger, A. J., & Maniker, A. H. (1992). MRI-documented regression of a herniated cervical nucleus pulposus: a case report. *Surgical neurology*, 37(6), 457-459.
6. Slavin, K. V., Raja, A., Thornton, J., & Wagner Jr, F. C. (2001). Spontaneous regression of a large lumbar disc herniation: Report of an illustrative case. *Surgical neurology*, 56(5), 333-336.
7. Rahimizadeh, A., Hassani, V., Asgari, N., & Hamidifard, M. (2018). Spontaneous Regression of the Sequestered Cervical Discs: A Prospective Study of 70 Cases.
8. Turk, O., & Yaldiz, C. (2019). Spontaneous regression of cervical discs: Retrospective analysis of 14 cases. *Medicine*, 98(7).
9. Choi, J. W., Lim, H. W., Lee, J. Y., Lee, W. I., Lee, E. K., Chang, C. H., ... & Sim, W. S. (2016). Effect of cervical interlaminar epidural steroid injection: analysis according to the neck pain patterns and MRI findings. *The Korean journal of pain*, 29(2), 96.